

Extraction of Intraocular Foreign Bodies by Pars plana Vitrectomy

A Retrospective Study

Hernando Camacho, Luis Fernando Mejía

Clínica Barraquer, Bogotá, Colombia

Key Words. Ocular trauma · Intraocular foreign body · Ambulatory vision · Vitreous hemorrhage

Abstract. We reviewed the medical records of 44 patients who underwent a pars plana vitrectomy to remove posttraumatic intraocular foreign bodies. The group most affected was that of males with a mean age of 28 years, who sustained a job injury, presenting with a single corneal laceration less than 2 mm in extension. There were 31 (70.45%) metallic foreign bodies. At surgery, 27 (61.36%) of the 44 foreign bodies were removed with forceps and 17 (38.63%) with the rare-earth magnet. From these patients, 84.61% obtained a final visual acuity equal or better than that on admission. We did not find a statistically significant difference between the groups with different timing on their vitrectomy, nor between groups presenting with and without vitreous hemorrhage.

Introduction

Penetrating lesions to the ocular globe are still an important cause of ocular morbidity, although their incidence is slowly decreasing thanks to a greater awareness about them and to the use of specialized protective equipment both at work and sports. However, this type of pathology is still too frequent and represents considerable difficulty in its management, primarily when there are intraocular foreign bodies (IOFBs).

Among all ocular perforations, IOFBs are found in a variable but significant percentage of cases (up to 35.8–40%) [1, 2]. De Juan et al.

[3] reported a series of 453 patients seen at the Wilmer Institute in which the main causes of the perforation were found to be bullets (41%), lacerations (37%) and blunt trauma (22%).

For some years, the prognosis for anterior segment trauma has improved considerably, due to the use of microsurgery, but it has remained the same for cases of posterior segment trauma [4]. Fortunately there has been a trend toward an improvement in the prognosis of these posterior segment trauma cases in recent years due to the use of more precise microsurgical techniques and to an earlier and more aggressive management of these patients [5–9]. As an example, only 6% of those eyes

treated at the Johns Hopkins Hospital between 1952 and 1970 [10] achieved a visual acuity equal to or better than 5/200, while 31% of such eyes treated at the same place between 1970 and 1981 attained this visual acuity [3].

Notwithstanding the prognosis in cases with an IOFB is usually better than that of blunt trauma [1, 11], there is a series of factors that make the decision to be taken in the former case difficult, such as the size, shape, course and material of the foreign body, the inflammatory response, the location and magnitude of the tissue damage and the time elapsed between the occurrence of the trauma and the surgery [12–15]. All these factors make it difficult to evaluate and standardize the management of this type of patients.

De Juan et al. [3, 16] have suggested the following parameters as indicators of poor prognosis when considering penetrating ocular trauma: low preoperative visual acuity, presence of an afferent pupillary defect, lesion caused by an obtuse object, initial lesion with scleral extension up to the insertion of the extraocular recti muscles, presence of a traumatic cataract and presence and density of a vitreous hemorrhage.

Among the many controversies about the posttraumatic IOFB management, two of the most frequent concern the ideal timing of the vitrectomy [8, 17] and the instrument to be used to remove the foreign body [7].

Regarding the first issue, the so-called 'early vitrectomy' (performed during the first 72 h after trauma) has been slowly gaining acceptance as the correct procedure in these patients [1, 6, 7, 11, 14, 18].

Referring to the type of instrument to be used in removing the IOFB [13, 19, 20], both the magnet (electromagnet and rare-earth magnet) and the forceps have been suggested with valid arguments.

Patients and Methods

The medical records of those patients which underwent a vitrectomy due to a posttraumatic IOFB between June 1984 and June 1989 at the Clínica Barraquer (Bogotá, Colombia) were reviewed. In all cases there had to be a minimum postoperative follow-up of 6 months, with anatomical and functional (visual acuity) control at 1 and 6 months. All patients were operated upon and followed up by one of the authors (H.C.).

The foreign body location was established by physical examination (indirect ophthalmoscopy), sometimes with the aid of paraclinical methods such as echography, X-rays or computed tomography scan.

In all cases a pars plana vitrectomy was performed, and the IOFBs were removed by means of forceps or the intraocular magnet of Parel through the sclerotomy. During surgery a number of different procedures were used when deemed necessary (scleral buckle, silicone oil, endolaser, cryopexy, lensectomy).

The statistical analysis was based on Fisher's test and the paired *t* test.

Results

From a total of 249 vitrectomies performed in cases of ocular trauma in the years specified, 44 (17.67%) were done on patients with post-traumatic IOFBs.

These 44 patients had the following characteristics: male sex 41 (93.18%), female 3 (6.81%); mean age 28.7 years (range 6–78 years); the age group distribution is shown in figure 1.

Regarding the characteristics of the wound, 42 were single (95.45%), 1 multiple (2.27%) and 1 double perforating (2.27%); the location was corneal in 59.09% (26), corneoscleral in 15.90% (7) and scleral in 25% (11); their size was less than 2 mm in 54.54% (24), from 2 to 5 mm in 45.45% (20) and none greater than 5 mm.

The foreign body entered the eye most frequently through the cornea (26 cases; 59.09%),

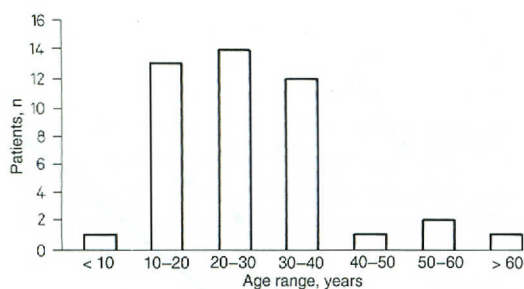


Fig. 1. Patient distribution by age groups.

followed in decreasing frequency by the pars plana (8 cases; 18.18%), limbus (8 cases; 18.18%) and equator (2 cases; 4.54%).

The most frequent causes of the trauma were job injury (32 cases; 72.72%), violence (6 cases; 13.63%) and various (6 cases; 13.63%).

Primary closure was accomplished in 3 patients. The vitrectomy was accomplished on different opportunities, depending on the patient general status and the moment it arrived, as follows: 'immediate' vitrectomy (done ≤ 72 h after the trauma) was performed in 20.45% of the patients (9), 'early' vitrectomy from the 4th to the 15th day was performed in 29.54% of the patients (13) and 'late' vitrectomy (after the 15th day) was done in 50% of the patients (22).

At surgery, 27 (61.36%) of the 44 foreign bodies were removed with forceps and 17 (38.63%) with the rare-earth magnet. The mean size of the objects ousted was $2.7 (\pm 1.24)$ mm by $1.43 (\pm 0.62)$ mm, with a range of 0.5–5 and 0.5–3 mm, respectively.

There were 31 (70.45%) metallic foreign bodies and 7 (15.90%) nonmetallic ones. The later group included stones, glass and a vegetal thorn. Information regarding the other 6 foreign bodies was lacking on the medical records.

These foreign bodies were removed most frequently through the sclerotomy (40) made for the vitrectomy, while only a few of them (4) were removed through a corneoscleral incision because of their greater size (mean size 3.25 by 2.25 mm).

The foreign body location was distributed as follows: lens (1), behind the iris (3), anterior vitreous (4), middle vitreous (8), posterior vitreous (6), peripheral retina (5) and posterior pole (17).

The most common findings on the initial examination were vitreous hemorrhage in 23 patients (52.27%), retinal detachment in 9 patients (20.45%) – 6 cases rhegmatogenous and 3 nonrhegmatogenous –, proliferative vitreoretinopathy in 7 patients (15.9%) and retinal tears in 7 patients (15.9%).

The complementary procedures most commonly used at surgery were scleral buckle in 32 cases (72.72%), lensectomy in 24 cases (54.54%), and cryopexy and endolaser in 18 cases each (40.90%).

Considering a visual acuity of 5/200 as the ambulatory vision, in our study 63.1% of the patients presented it upon admission, and 84.21% presented it on the last examination (6 months minimum follow-up).

From these patients, 14 (53.84%) got a 'good' visual acuity ($\geq 20/40$), 4 (15.38%) a 'useful' visual acuity (20/40–20/300) and 8 (30.76%) a 'poor' one ($< 20/300$).

The overall visual acuity measured on the last examination (minimum follow-up of 6 months) was distributed as shown in table 1.

As a whole, from the 26 patients with their visual acuity recorded at least at 6 months, 4 (15.38%) had an inferior visual acuity than at the first visit (deterioration of two or more lines on the Snellen chart), 7 (26.92%) got the same one (change of less than two lines on the Snellen chart) and 15 (57.69%) improved (increase of two or more lines on the Snellen

Table 1. Overall final visual acuity

Visual acuity		Number of patients	Percentage
Snellen	decimal		
20/20	1.00	9	31.03
20/25–20/40	0.8–0.5	7	24.13
20/50	0.4	2	6.89
20/60	0.33	1	3.44
20/100	0.2	2	6.89
20/125–20/200	0.16	0	0
20/400	0.05	1	3.44
20/800	0.025	0	0
HM–CF		5	17.24
LP		1	3.44
NLP		1	3.44
Total		29	100

HM = Hand movements; CF = counting fingers; LP = Light perception; NLP = no light perception.

Table 2. Relation between final visual acuity (VA) and timing of vitrectomy

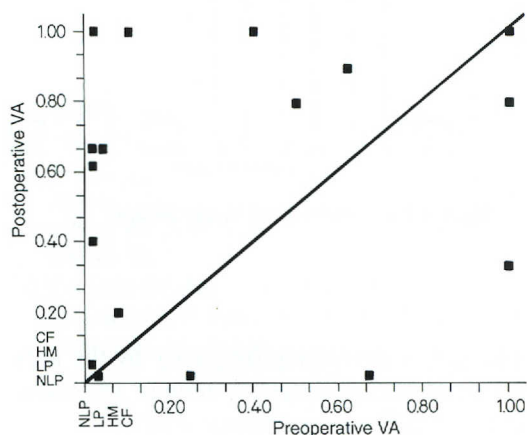
Timing	Worse VA	Same VA	Better VA	Total
Immediate	1 (16.66)	1 (16.66)	4 (66.66)	6
Early	2 (20)	3 (30)	5 (50)	10
Late	1 (10)	3 (30)	6 (60)	10
Total	4	7	15	26

Figures in parentheses indicate percentages.

chart). The comparison between the visual acuity at the first visit and that at the last control is shown in figure 2.

Table 2 shows the visual acuity results related to the timing of vitrectomy after the trauma.

From the 23 patients presenting with a vitreous hemorrhage – considered as a poor prognosis factor –, 14 had a minimum follow-up of

**Fig. 2.** Visual acuity (VA) at first visit (n = 26) and last visit. CF = Counting fingers; HM = hand motion; LP = light perception; NLP = no light perception.**Table 3.** Relation between presence of vitreous hemorrhage and final visual acuity (VA)

Vitreous hemorrhage	Worse VA	Same VA	Better VA	Total
Present	3 (21.42)	3 (21.42)	8 (57.14)	14
Absent	1 (8.33)	4 (33.33)	7 (58.33)	12
Total	4	7	15	26

Figures in parentheses indicate percentages.

6 months with visual acuity examination; from these, 3 (21.42%) got a worse visual acuity, 3 (21.42%) the same one and 8 (57.14%) a better one.

Table 3 shows the comparison of the variation in visual acuity at the first visit and last control between the groups with and without vitreous hemorrhage.

Among the early postoperative complications there were 1 case of vitreous hemorrhage (2.27%), 1 case of cataract (2.27%), 6 cases of retinal detachment (13.63%), 3 cases of proliferative vitreoretinopathy (6.81%), 1 case of silicone-oil-induced keratopathy (2.27%) and 1 case of silicone-oil-induced ocular hypertension (2.27%).

From the anatomical standpoint, the final results were applied retina in 37 patients (84.09%), retinal detachment in 5 (11.36%), macular scar in 3 (6.81%), proliferative vitreoretinopathy in 2 (4.54%) and phthisis bulbi in 1 (2.27%).

Discussion

On our service we perform a vitrectomy plus removal of IOFB on most patients with posttraumatic IOFBs, for several reasons:

- In a great percentage of these patients there are media opacities which impede an adequate evaluation of the retina. By doing a vitrectomy we are allowed to completely visualize the whole retina, and we remove a foreign body which – most likely – will cause problems in the future.

- Due to the cultural and economic characteristics of our country, we have decided not to follow up on these patients based on electrophysiological studies and/or clinical examination alone (without surgery) because many of them never return to successive controls because they are not experiencing any immediate consequences of their IOFB. Proof of this is the fact that many of the patients we operated upon (18 out of 44; 40.9%) did not return for the minimum follow-up required by our protocol (6 months); similar or even greater percentages of patient dropouts have been described by others [21]. However in some pa-

tients in whom the IOFB does not cause apparent damage and who can be confidently followed up clinically, we do so for as long as possible.

Our results are similar to those obtained by other investigators at different centers [5, 8, 11]. According to this, the group most frequently involved is that of young males, the most frequent lesion is the single corneal one and the most frequent cause is a job injury (usually caused by the use of a hammer on a chisel or metal).

It is important to note that in our series there is a disproportionately high number of patients (50%) that underwent 'late' vitrectomy which discloses a lack of awareness among patients and physicians regarding the urgency of these cases and its need to be managed cooperatively by both the anterior segment and the retina and vitreous surgeons; in the many reports available in the present literature about ocular trauma, the celerity of the beginning of treatment has become prominent in the prognosis for the eye.

Although it did not reach a statistical level of significance, it is important to remark that – as a group – the patients that underwent 'immediate' vitrectomy obtained a somewhat greater improvement in their visual acuity (66% of these patients' visual acuity improved, when compared to that on admission) in comparison with that of the group that underwent 'early' vitrectomy (50% improved) and 'late' vitrectomy (60% improved). A possible reason for the small difference in these results is that those patients that suffer a particularly severe trauma come to the office or are referred earlier than those who suffer a lesser trauma; in the former group, the prognosis is considered worse from the beginning.

When the foreign body is embedded in the retina and is difficult to remove, we use Ma-

cherner's forceps with diamond coating because it allows better handling of the object and also a better dissection of the tissue adjacent to it during the process of extraction. In those cases in which the foreign body is free in the vitreous cavity or is just resting on the retinal surface, we employ the rare-earth magnet, because this magnet cannot be inactivated and will not spontaneously release the object.

As has been recently published the surgical results of the group of patients with IOFBs are considerably better than those of the group of ocular trauma as a whole [5].

In this report, 84.59% of the patients followed up for at least 6 months gained a visual acuity which was equal or better than that recorded at the first visit. Their mean visual acuity at the first visit was 0.238, and that at the last control was 0.516, which is statistically significant ($p=0.01$).

It is important to note that 73.07% (19) of the patients followed up for at least 6 months achieved an ambulatory vision (5/200 or better), which compares favorably with previously published reports.

Patients presenting from the beginning with a vitreous hemorrhage did not obtain a final visual acuity as good as that of those which did not have vitreous hemorrhage upon admission (78.56 and 91.66%, respectively, maintained or improved their initial visual acuity), as reported by other authors [8]; however, this difference was not statistically significant ($p=0.63$).

A feasible explanation for the differences between ours and other papers is the fact that most of the reports – as well as ours – on this topic are based on small numbers of patients which permits a great variability of the results from the statistical point of view.

Finally, it is important to emphasize the high percentage of anatomical success (84.09% of the retinas adhered at the end of the study)

which is a stimulus to operate on these patients earlier, trying to increase the fraction of patients that obtain both a good anatomical and functional result.

References

- 1 Brinton GS, Aaberg TM, Reeser FH, Topping TM, Abrams GW: Surgical results in ocular trauma involving the posterior segment. *Am J Ophthalmol* 1982;93:271.
- 2 Coleman DJ, Lucas BC, Rondeau MJ, Chang S: Management of intraocular foreign bodies. *Ophthalmology* 1987;94:1647.
- 3 De Juan E, Sternberg P Jr, Michels RG: Penetrating ocular injuries. Types of injuries and visual results. *Ophthalmology* 1983;90:1318.
- 4 Williams D, Mieler W, Abrams G: Intraocular foreign bodies in young people. *Retina* 1990;10 (suppl 1):S45.
- 5 Sternberg P Jr, Aaberg TM: The persistent challenge of ocular trauma. *Am J Ophthalmol* 1989;107:421.
- 6 Brinton GS, Aaberg TM: Changing aspects of management of ocular trauma. *Am J Ophthalmol* 1982;94:258.
- 7 Meredith TA, Gordon PA: Pars plana vitrectomy for severe penetrating injury with posterior segment involvement. *Am J Ophthalmol* 1987;103:549.
- 8 Coleman DJ: Early vitrectomy in the management of the severely traumatized eye. *Am J Ophthalmol* 1982;93:543.
- 9 Skorpik C, Menapace R, Gnad HD, Paroussis P: Silicone oil implantation in penetrating injuries complicated by PVR. *Retina* 1989;9:8.
- 10 Cherry PMH: Rupture of the globe. *Arch Ophthalmol* 1972;88:498.
- 11 Neubauer H: Intraocular foreign bodies. *Trans Ophthalmol Soc UK* 1975;95:496.
- 12 De Juan E, Sternberg P Jr, Michels RG: Timing of vitrectomy after penetrating ocular injuries. *Ophthalmology* 1984;91:1072.
- 13 Potts AM, Distler JA: Shape factor in the penetration of intraocular foreign bodies. *Am J Ophthalmol* 1985;100:183.
- 14 Shock JP, Adams D: Long term visual acuity results after penetrating and perforating ocular injuries. *Am J Ophthalmol* 1985;100:714.

- 15 Heimann K, Paulmann H, Tavakolian U: The intraocular foreign body. Principles and problems in the management of complicated cases by pars plana vitrectomy. *Int Ophthalmol* 1983;6:235-242.
- 16 De Juan E Jr, Sternberg P Jr, Michels RG, Auer C: Evaluation of vitrectomy in penetrating ocular trauma: A case control study. *Arch Ophthalmol* 1984;102:1160.
- 17 De Bustros J, Michels R, Glaser B: Evolving concepts in the management of posterior segment penetrating ocular injuries. *Retina* 1990;10(suppl 1):S72.
- 18 Ryan SJ, Allen AW: Pars plana vitrectomy in ocular trauma. *Am J Ophthalmol* 1979;88:483.
- 19 Heimann K: Pars-plana-vitrectomy in the treatment of injuries with intraocular foreign bodies. *Bull Soc Belge Ophthalmol* 1981;193:13-24.
- 20 Cupples HP, Whitmore PV, Wertz FD, Mazur DO: Ocular trauma treated by vitreous surgery. *Retina* 1984;3:103.
- 21 Heimann K, Neubauer H, Paulmann H, Tavakolian U: Pars plana vitrectomy after intraocular foreign bodies. *Mod probl Ophthalmol* 1979;20:247-255.

Received: December 16, 1990

Accepted: December 19, 1990

Hernando Carnacho, MD
Retina and Vitreous Department
Instituto Barraquer de América
Bogotá (Colombia)