
Piggyback posterior chamber multifocal intraocular lenses in anisometropia

Luis F. Mejía, MD

ABSTRACT

A 63-year-old white man with anisometropic hyperopia presented with cataract in both eyes. He had uneventful temporal limbal phacoemulsification with intracapsular placement of a multifocal 3-piece silicone intraocular lens (IOL) in his right eye (model SA-40N, Allergan, Inc.). One week later, 2 intracapsular 3-piece silicone IOLs (1 monofocal backward, Allergan model SI-40NB; 1 multifocal in front, Allergan model SA-40N) were implanted in his left eye. At 8 days postoperatively, uncorrected visual acuity was 20/20 for distance and J1 for near vision in the right eye and 20/30 and J2, respectively, in the left. These values remained constant until the patient was seen 7 months postoperatively. Power calculation and insertion order of the piggyback IOLs were considered. *J Cataract Refract Surg* 1999; 25:1682–1684 © 1999 ASCRS and ESCRS

The implantation of 2 or more intraocular lenses (IOLs) to provide adequate power in a case of microphthalmos was first described by Gayton and Sanders.¹ Several reports have since described using piggyback IOLs for similar² or different reasons such as postoperative pseudophakic refractive errors (J.P. Gills, MD, “Implantation of Multiple Intraocular Lenses to Optimize Visual Results,” presented at the Symposium on Cataract, IOL and Refractive Surgery, San Diego, California, USA, April 1995) and postpenetrating keratoplasty.³ These reports share the difficulty of obtaining a predictable IOL power calculation because of extremely short axial lengths or preoperative ophthalmic surgical history.

Several IOL materials—acrylic, poly(methyl methacrylate), and silicone—have been used with com-

parably good results.³ Piggyback posterior chamber IOLs have gained acceptance, because they have proved easier to implant and more predictable than IOL exchange. I present a case of piggyback multifocal silicone IOL implantation in a long-time known patient with anisometropic hyperopia who developed a senile cataract.

Case Report

In November 1998, a 63-year-old white man, who had anisometropic hyperopia with a higher refractive error in the left eye, adequately corrected with glasses presented with poor vision in both eyes. His previous refraction had been +2.50 –0.50 × 180 in the right eye and +7.50 –2.50 × 60 in the left, with a best corrected visual acuity (BCVA) of 20/20 and 20/30⁺, respectively. The current findings were a BCVA of 20/50 in the right eye and 20/70 in the left; K-readings of 42.50 × 10/43.50 × 100 and 44.00 × 130/45.75 × 40, respectively; and axial lengths of 22.84 and 21.41 mm, respectively. There was a posterior subcapsular cataract in both eyes, more advanced in the left.

The patient was enthusiastic about using multifocal IOLs, open-minded, and optimistic. He understood and accepted the possibility of night halos, less quality of vision than with monofocal IOLs, and the need for near-vision glasses when reading for long periods.

Accepted for publication August 10, 1999.

From the Cornea Service, Instituto de Ciencias de la Salud, CES, Medellín, Colombia.

The author has no financial or proprietary interest in any product or method mentioned.

Reprint requests to Luis F. Mejía, MD, Clínica SOMA, Calle 51 #45-93, Cons #307, Medellín, Colombia.

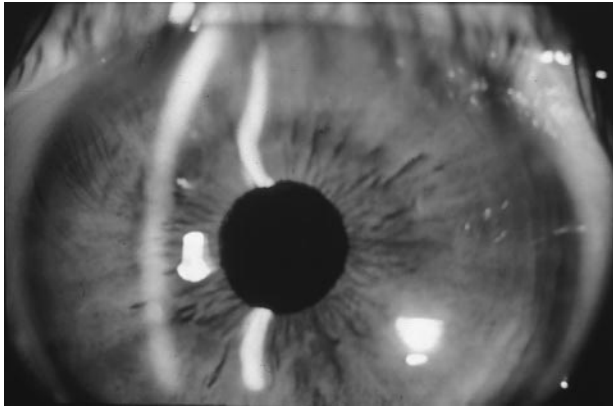


Figure 1. (Mejía) Left eye. Note the 2 slits on the pupil corresponding to the multifocal (anterior) and monofocal (posterior) IOLs.

Under peribulbar anesthesia, a temporal limbal incision was made in the right eye. Uneventful stop and chop phacoemulsification (Protegé, Storz) with intracapsular implantation of a posterior chamber, multifocal, 3-piece silicone, +22.5 diopters (D) IOL (model SA-40N, Allergan) was performed. The postoperative course was uneventful. At 8 days, the patient's uncorrected visual acuity (UCVA) was 20/20 for distance and J1 for near vision, with a residual distance refractive error of plano -0.50×180 . It remained the same 7 months postoperatively.

One week postoperatively, the patient's left eye was operated on using the same surgical technique. A lower power (+12.0 D) posterior chamber, monofocal, 3-piece silicone IOL (model SI-40NB, Allergan) was implanted backward with a multifocal (+16.0 D), 3-piece silicone IOL (model SA-40N) on top of it. Both IOLs were implanted intracapsularly, with the haptics aligned (Figures 1 and 2). The postoperative course was uneventful. At 8 days, the patient's UCVA and BCVA were 20/30 and 20/25, respectively, for distance and J2 and J2+, respectively, for near, with a residual distance refractive error of $+0.75 - 1.00 \times 50$. These values remained unchanged 7 months postoperatively.

Patient satisfaction was assessed by a standardized questionnaire that was given to all multifocal IOL patients. It asked about quantity and quality of vision, halos, need for glasses for far or near vision and night driving, and percentage of time not using glasses for far or near vision. Upon direct questioning, the patient reported initial nontroublesome halos in both eyes, which disappeared at the end of the first month.

Discussion

Multifocal IOLs have generated both controversy and high expectation among ophthalmologists and patients. Several models have been released to the market

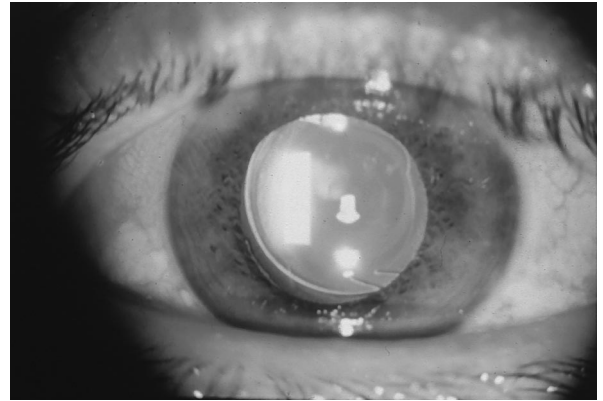


Figure 2. (Mejía) Left eye. Note the inferior haptic of each IOL, almost parallel near the pupillary margin between 5 and 6 o'clock, and the optical zones of the multifocal IOL shown by retroillumination.

only to show poor results because of decentration, halos, and loss of BCVA.

The SA-40N multifocal IOL has been used extensively in Europe and recently in the United States with good results.⁴⁻⁶ Strict patient selection guidelines, have been suggested by the manufacturer and investigators; e.g., avoiding patients who are professional night drivers or have pre-existing corneal astigmatism greater than 1.5 D, perfectionist personalities, abnormal pupils, or contralateral monofocal pseudophakia, and including those with good ophthalmic health who are highly motivated not to use glasses and willing to accept nuisances such as transient halos (Expert Panel, "Advances in Multifocal Lens Technology. The AMO Array," Ocular Surgery News, April 1, 1998, pages 2 to 15).⁷

Implanting a piggyback multifocal IOL involves several difficulties: the calculation of the IOL powers, the selection of the IOL to place more posteriorly, and the behavior of the multifocality of the IOL in a piggyback mode. I used Holladay IOL consultant software, which has a piggyback IOL option. Because the minimum power of the multifocal IOL model that was available in Colombia was +16.00 D, I had to place the lower power IOL backward and the higher power IOL forward in the capsular bag, as opposed to piggybacking monofocal IOLs.² As the multifocality of this IOL design lies in its anterior surface, I placed it on top of the monofocal IOL in the capsular bag.

While piggyback IOL implantation is a sound and safe alternative, patients must be informed about interlenticular opacification and hyperopic shift over

time that have been reported in eyes with foldable piggyback IOLs (J. L. Gayton, MD, V. Sanders, MD, M. Van der Karr, MD, "Long-Term Membrane Formation Between Piggybacked Implants," presented at the Symposium on Cataract, IOL and Refractive Surgery, Seattle, Washington, USA, April 1999). I agree with the manufacturer's and experienced surgeons' strict guidelines for implantation of this multifocal IOL. However, I believe that with good patient selection and counseling and a sound surgical technique, this multifocal IOL can be piggybacked with excellent results in eyes with marked anisometropia.

References

1. Gayton JL, Sanders VN. Implanting two posterior chamber intraocular lenses in a case of microphthalmos. *J Cataract Refract Surg* 1993; 19:776–777
2. Holladay JT, Gills JP, Leidlein J, Cherchio M. Achieving emmetropia in extremely short eyes with two piggyback posterior chamber intraocular lenses. *Ophthalmology* 1996; 103:1118–1123
3. Gayton JL, Sanders V, Van der Karr M, Raanan MG. Piggybacking intraocular implants to correct pseudophakic refractive error. *Ophthalmology* 1999; 106:56–59
4. Arens B, Freudenthaler N, Quentin CD. Binocular function after bilateral implantation of monofocal and refractive multifocal intraocular lenses. *J Cataract Refract Surg* 1999; 25:399–404
5. Pieh S, Weghaupt H, Skorpik C. Contrast sensitivity and glare disability with diffractive and refractive multifocal intraocular lenses. *J Cataract Refract Surg* 1998; 24:659–662
6. Vaquero-Ruano M, Encinas JL, Millan I, et al. AMO Array multifocal versus monofocal intraocular lenses: long-term follow-up. *J Cataract Refract Surg* 1998; 24:118–123
7. Javitt JC, Wang F, Trentacost D, et al. Outcomes of cataract extraction with multifocal intraocular lens implantation: functional status and quality of life. *Ophthalmology* 1997; 104:589–599