

## Silicone Oil in the Management of Giant Retinal Tears

HERNANDO CAMACHO, MD, BORIS BAJAIRE, MD, AND LUIS FERNANDO MEJIA, MD

*To evaluate the results of using and removing silicone oil in the management of giant retinal tears, 24 cases of vitrectomy with fluid-silicone oil exchange were reviewed. We did not use cryotherapy in any case. For chorioretinal adherence, we used either endolaser or postoperative external laser and a narrow buckle. The retina was reattached successfully in 22 (91.6%) of the 24 eyes. Of these, visual acuity was 20/200 or better in 18 (75%) eyes. This was significantly better than the preoperative visual acuity ( $P = .02$ ). After removing the silicone oil in 15 cases, 13 (92.8%) had visual acuities of 20/200 or better, which was considerably better than that of the group in which the silicone oil was not removed ( $P = .006$ ). We recommend removing the silicone oil and additional peeling of membranes an average of six months postoperatively when the eye is stable.*

Giant retinal tears pose a great challenge to the retina and vitreous surgeon, not only because of the difficulty of handling them during surgery, but also because of the many complications that can occur during the follow-up period after apparently successful surgery. The use of pars plana vitrectomy with fluid-silicone oil exchange has been a standard method for managing giant retinal tears at various European centers.<sup>1-4</sup> We describe the results of treating giant retinal tears with this technique, which we have been using since 1985.

### Patients and Methods

The hospital records of 25 patients (27 eyes) with giant retinal tears and inverted flaps operated on and followed by one of the authors at Clinica Barraquer (Bogota, Colombia) between November 1985 and November 1989 were reviewed. Two patients were excluded because their follow-up was < six months.

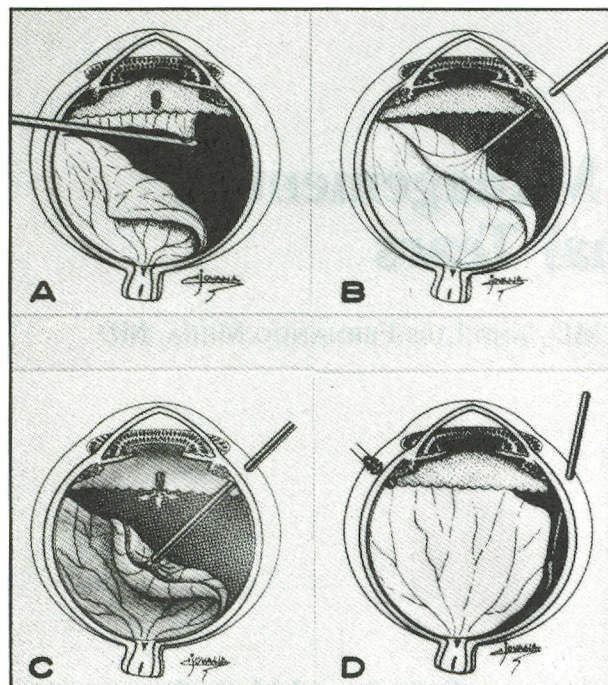
In all cases, a three-port pars plana vitrectomy was done,<sup>5</sup> with a lensectomy and extensive vitrectomy at the vitreous base (Figure 1). Care was taken to remove the vitreous base and, simultaneously, the peripheral tear edge of the giant retinal tear. An inferior peripheral iridectomy was done with the vitrectome. Then the posterior flap of the giant retinal tear was unfolded by means of direct manipulation with the brush back flush needle<sup>5</sup> and the optical pipe, while simultaneously injecting silicone oil (1000 or 5000 cps) with the aid of an infusion pump (VFI/VFE unit, Dore). At the same

From the Retina and Vitreous Department, Instituto Barraquer de America, Bogota, Colombia.

Presented at the XVIIth Meeting of the Club Jules Gonin, Lausanne, Switzerland, September 2 to 6, 1990.

Address for reprints: Hernando Camacho, MD, Retina and Vitreous Department, Clinica Barraquer, Apartado Aereo #90-404, Bogota, Colombia.





**Figure 1** (a). Removal of the peripheral tear edge of the giant retinal tear. (b). Unfolding of the posterior flap of the giant retinal tear by means of direct manipulation with the brush back flush needle.<sup>5</sup> (c). Injection of silicone oil with the aid of an infusion pump; at the same time, a fluid-silicone oil exchange was done with the back flush needle. (d). Finally, the residual liquid was drained through the posterior border of the tear.

time, a fluid-silicone oil exchange was done with the back flush needle until the retina was reattached completely. Finally, the residual liquid was drained through the posterior border of the tear, and the endolaser (or postoperative laser) was applied. Cryotherapy was not used in any case. At the end of the procedure, an encircling band (#240 silicone band or #503 silastic sponge) was positioned. In most cases, a Landers lens set was used, but during the later cases, the binocular indirect ophthalmomicroscope and stereoscopic diagonal inverter system<sup>6,7</sup> was preferred.

When the silicone oil was removed, we used a three-port pars plana approach with a vacuum pump.<sup>5</sup> After this, a careful revision of the retina was done, and we peeled off any perisilicone or epiretinal membranes when found. Finally, endolaser treatment was applied when deemed necessary.

To establish the characteristics of the eyes with giant retinal tears, the following characteristics were considered: the patient's sex and age at the time of the first visit; medical history

regarding myopia, retinal detachment from any cause, and giant retinal tear; associated retinal lesions; history of recent trauma to the affected eye; family history of myopia, retinal detachment, and giant retinal tear; and location and extent of the giant retinal tear.

## Results

### Sex and Age

We treated 16 (69.5%) men and seven (30.4%) women. The mean patient age was 39 years (range, 13–75 years). The mean follow-up was 20.2 months (range, 6–70 months).

### Refractive Error

Nine (39.1%) patients were myopic, distributed as follows: five (21.7%) had less than 10D of myopia and four (17.3%) had 10 to 20D of myopia. No patient had myopia > 20D.

### History of Retinal Lesions

Four (17.3%) patients had had a retinal detachment in the contralateral eye; one (4.34%) had had a giant retinal tear in the fellow eye four months earlier. In six (25%) patients, there was a history of ocular trauma, which was penetrating in four and blunt in two. There was no family history of giant retinal tears.

Initial examination showed aphakia or pseudophakia in 13 (54.16%) eyes. Of these, five had had an extracapsular cataract extraction (ECCE) with a posterior-chamber intraocular lens placed, one had had an ECCE, and seven had had an intracapsular cataract extraction with an anterior-chamber intraocular lens placed in one patient. The average extension of the giant retinal tear was  $185^\circ (\pm 63^\circ)$ . The distribution is shown in Table I. The giant retinal tear was located most frequently in the superior quadrant (24 eyes), followed by the temporal (22 eyes), inferior (14 eyes), and nasal (12 eyes) quadrants. The anterior edge of the tear was rolled up in all cases, and there was macular involvement produced by a retinal detachment in 19 eyes (79.16%). On initial examination of the affected eye, proliferative vitreoretinopathy was found in seven eyes (29% of cases), vitreous hemorrhage in five (20.8%), horseshoe tears in two (8.3%), and lattice degeneration and macular hole in one (4.16%) each. Including silicone oil removal, an average of  $1.95 (\pm 0.9)$  operations per eye were done.

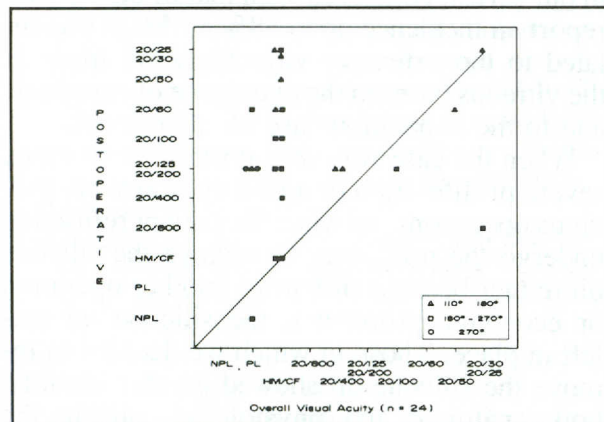


**Table I** Extension of the Giant Retinal Tear

Group	Extension	No. of Eyes	Percentage
A	110 to <180°	9	37.5
B	180 to 270°	13	54.16
C	>270°	2	8.33
Total		24	100

**Table II** Overall Final Visual Acuity

Visual Acuity	Group A	Group B	Group C	Total (%)
20/25-20/40	3	1	0	4 (16.66)
20/50-20/100	3	3	0	6 (25)
<20/100-20/400	3	6	2	11 (45.83)
20/800	0	1	0	1 (4.16)
<20/800	0	2	0	2 (8.33)
Total	9	13	2	24

**Figure 2.** Overall visual acuity.

### Visual Acuity

Visual acuity improved (change in two or more Snellen lines) in 72.22% of cases and deteriorated in 27.77% (Figure 2). A final visual acuity equal to or better than 20/200 was obtained in 18 (75%) cases (Table II).

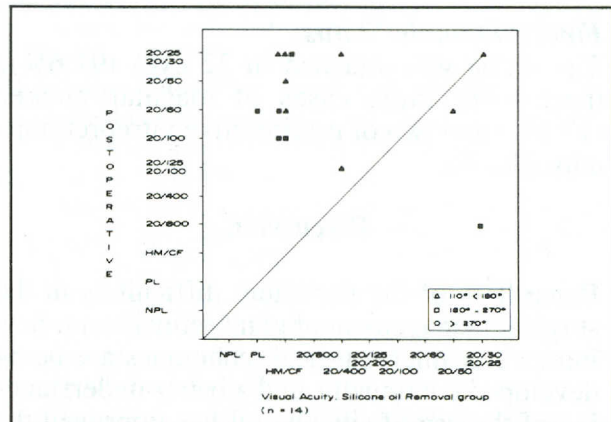
The silicone oil was removed in 15 patients in an average of 8.1 ( $\pm 4.6$  months; range, 3-18 months). In one of these patients, the retina detached again after silicone oil extraction, and it was necessary to reinject it. Of these, 13 (92.85%) patients had a final visual acuity

**Table III** Final Visual Acuity in Silicone Oil-Extraction Group

Visual Acuity	Group A	Group B	Group C	Total (%)
20/25-20/40	3	1	0	4 (28.57)
20/50-20/100	3	3	0	6 (42.85)
<20/100-20/400	2	1	0	3 (21.42)
20/800	0	1	0	1 (7.14)
Total	8	6	0	14

**Table IV** Final Visual Acuity in Group With Silicone Oil Retained

Visual Acuity	Group A	Group B	Group C	Total (%)
20/25-20/40	0	0	0	0 (0)
20/50-20/100	0	0	0	0 (0)
<20/100-20/400	0	5	2	7 (70)
20/800	0	0	0	0 (0)
<20/800	0	3	0	3 (30)
Total	0	8	2	10

**Figure 3.** Visual acuity in the silicone-removed group.

equal to or greater than 20/200 (Figure 3, Table III).

The final visual acuity in the group in which the silicone oil was not removed is shown in Table IV. In these patients, the final visual acuity was equal to or better than 20/200 in 60% of the cases (Figure 4).

### Postoperative Complications

There were seven cases of macular pucker (29.1%), four of proliferative vitreoretinopathy (16.6%) and two of reoperation among



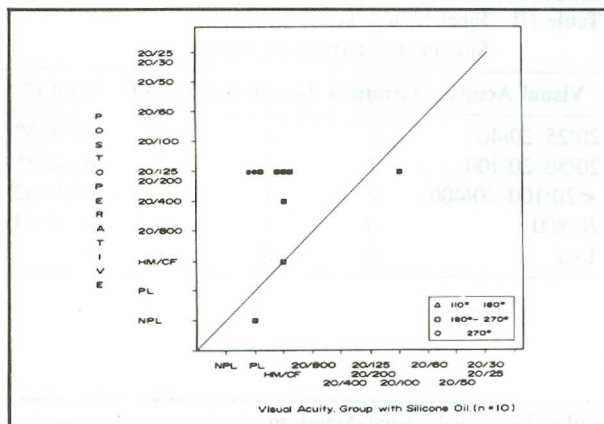


Figure 4. Visual acuity in the silicone-retained group.

seven patients with preexisting proliferative vitreoretinopathy (28.5%).

The complications secondary to the silicone oil were: three cases of keratopathy (2, band keratopathy and 1, bullous keratopathy), three cases of ocular hypertension, one case of oil in the anterior chamber, and two cases of optic nerve atrophy.

#### Final Anatomic Status

The retina was attached in 22 eyes (91.6%); there were three cases of macular pucker (12.5%) and two of proliferative vitreoretinopathy (8.3%).

#### Discussion

Regardless of the persistent difficulties in the surgical management of giant retinal tears, new intraocular microsurgical techniques are being developed continually, and a better understanding of the use of silicone oil has improved the long-term prognosis in this condition.<sup>8-10</sup> We believe that silicone oil injection for the management of giant retinal tears has some advantages over gas injection.<sup>11-18</sup> Among these is the prolonged internal tamponade which impedes the posterior edge of the giant retinal tear from slipping and changes the vector forces generated by periretinal membranes from a perpendicular to a tangential orientation in cases of proliferative vitreoretinopathy.<sup>19</sup> We also found that, as a result of the optical properties of silicone oil, both the endolaser and the postoperative laser can be applied with greater facility and safety than when a gas bubble is present. Another advantage is that a conventional stretcher can be used during surgery,

making it easier for the operating team.

We do not consider broad buckles to be necessary for the management of giant retinal tears, as others have suggested,<sup>20</sup> because this particular vitreoretinal pathologic condition must be handled internally, liberating adhesions and removing tissue that can serve as a scaffold for membrane growth, leaving a space for internal tamponade and repositioning the posterior edge of the giant retinal tear. However, a broad buckle alters the internal geometry of the eye, thus making the adequate reposition of the retinal borders difficult.<sup>5</sup>

Even though treatment with cryopexy produces enough adhesion to seal a giant retinal tear as a result of its action on the choroid and retinal pigment epithelium, we prefer to use the laser (either endolaser or postoperative) because this method produces the same result without exposing the eye to liberation of retinal pigment cells and the later induction of metaplastic activity that might lead to proliferative vitreoretinopathy.<sup>21,22</sup>

We think that the low incidence of postoperative proliferative vitreoretinopathy (16.66%) in our series, compared with that of others who report an incidence up to 58%,<sup>17,18,23,24</sup> was related to the extensive vitrectomy we made at the vitreous base, to the avoidance of cryopexy, and to the expeditious use of silicone oil.

When the case was very unstable with early, severe proliferation or a history of several previous operations, or when the patient refused to undergo the procedure to remove the silicone oil (either because of fear of another operation or economic problems), the silicone oil was left in place. Those in which we decided to remove the silicone oil showed greater stability, both anatomic and physiologic, during the postoperative evaluation and continued to do so during the follow-up period after silicone oil removal (for an average of 6 months). When it was deemed necessary, we repeated the peeling of epiretinal membranes during extraction of the silicone oil; this stabilized and improved the existing results. As a group, 92.85% of the cases in which the silicone oil was removed ( $n = 14$ ) had a final visual acuity of 20/200 or better. This was better than that obtained in the group ( $n = 10$ ) in which the silicone oil was not removed (60% had a final visual acuity of 20/200 or better;  $P = .0062$ ).

The use of the binocular indirect ophthalmomicroscope and stereoscopic diagonal inverter system<sup>6,7</sup> enabled us to visualize glo-



bally the status of the retina and examine precisely the borders of the giant retinal tear during the entire surgical procedure, allowing a better manipulation of the flap and subsequent endolaser placement up to the periphery.

### References

1. Laqua H: Current concepts in the management of complex retinal detachments. *Trans Ophthalmol Soc UK* 1983;103:133.
2. Leaver PK, Lean JS: Management of giant retinal tears using vitrectomy and silicone oil/fluid exchange. *Trans Ophthalmol Soc UK* 1981;101:189.
3. Lucke KH, Foerster MH, Laqua H: Long term results of vitrectomy and silicone oil in 500 cases of complicated retinal detachments. *Am J Ophthalmol* 1987;104:624-633.
4. Zivovnjovic R, Mertens DAE, Peperkamp E: Das flüssige Silikon in der Amotiochirurgie (II). Bericht über 280 Falle weitere Entwicklung der technik. *Klin Monatsbl Augenheilkd* 1982;181:444-452.
5. Zivovnjovic R (ed): *Silicone Oil in Vitreoretinal Surgery*. Dordrecht, Martinus Nijhoff/Dr W. Junk, 1987.
6. Spitznas M: A binocular indirect ophthalmomicroscope (BIOM) for non-contact wide-angle vitreous surgery. *Graefes Arch Clin Exp Ophthalmol* 1987;225:13-15.
7. Spitznas M, Reiner J: A stereoscopic diagonal inverter (SDI) for wide angle vitreous surgery. *Graefes Arch Clin Exp Ophthalmol* 1987;225:9-12.
8. Billington BM, Leaver PK: Vitrectomy and fluid/silicone oil exchange for giant retinal tears: Results at 18 months. *Graefes Arch Clin Exp Ophthalmol* 1986;224:7-10.
9. Leaver PK, Billington B: Vitrectomy and fluid/silicone oil exchange for giant retinal tears: 5 Years follow up. *Graefes Arch Clin Exp Ophthalmol* 1989;227:323-327.
10. Leaver PK, Cooling RJ, Lean SJ, et al: Vitrectomy and fluid/silicone oil exchange for giant retinal tears. Results at six months. *Br J Ophthalmol* 1984;68:432-438.
11. Charles S: Giant breaks, in Charles S (ed): *Vitreous Microsurgery*, 2nd ed. Baltimore, Williams & Wilkins, 1989; 172-181.
12. Fung W, Hall D, Cleasby G: Combined technique for a 355 degree traumatic giant retinal break. *Arch Ophthalmol* 1975;93:264-266.
13. Howard R, Gaasterland D: Giant retinal dialysis and tear. *Arch Ophthalmol* 1970;84:312-315.
14. Kanski J: Giant retinal tears. *Am J Ophthalmol* 1975;79:846-852.
15. Kreissig H, Lincoff H, Stanowsky A: The treatment of giant retinal detachments using retrohyaloidal perfluorocarbon gases without drainage or vitrectomy. *Graefes Arch Clin Exp Ophthalmol* 1987;225:94-98.
16. Kreeissig I, Stanowsky A, Lincoff H, et al: The treatment of difficult retinal detachments with an expanding gas bubble without vitrectomy. *Graefes Arch Clin Exp Ophthalmol* 1986;224:51-54.
17. Machemer R, Allen A: Retinal tears 180 degrees and greater. Management with vitrectomy and intravitreal gas. *Arch Ophthalmol* 1976;94:1340-1346.
18. Vidaurri-Leal J, DeBustros S, Michels RG: Surgical treatment of retinal tears with inverted posterior retinal flaps. *Am J Ophthalmol* 1984;98:463-466.
19. Glaser B: Treatment of giant retinal tears combined with proliferative vitreoretinopathy. *Ophthalmology* 1986;93:1193-1197.
20. Michels R, Rice T, Blankenship G: Surgical techniques for selected giant retinal tears. *Retina* 1983;3:139-153.
21. Campochiaro PA, Glaser BM: Mechanisms involved in retinal pigment epithelial cell chemotaxis. *Arch Ophthalmol* 1986;104:277-280.
22. Campochiaro PA, Jerdan JA, Glaser BM: Serum contains chemoattractants for human retinal pigment epithelial cells. *Arch Ophthalmol* 1984;102:1830-1833.
23. Freeman HM, Castillejos ME: Current management of giant retinal tears: Results with vitrectomy and total air-fluid exchange in 95 cases. *Trans Am Ophthalmol Soc* 1981;179:89.
24. Holland P, Smith T: Broad scleral buckle in the management of retinal detachment with giant tears. *Am J Ophthalmol* 1977;83:518.