

Comparison of 4 techniques for limbal-conjunctival autograft fixation in primary pterygium surgery

Luis F. Mejía¹, Juan P. Santamaría², Miguel Cuevas², Andrea Córdoba², Sergio A. Carvajal²

¹Cornea Service, CES University, Medellín - Colombia

²Ophthalmology Service, CES University, Medellín - Colombia

ABSTRACT

Purpose: To compare 4 limbal-conjunctival autograft fixation techniques—conventional suture, commercial fibrin glue, autologous fibrin glue, and cautery—in primary nasal pterygium surgery.

Methods: This is a retrospective and descriptive study. The postoperative patient discomfort, graft edema, ocular inflammation, and other complications of 4 limbal-conjunctival autograft fixation techniques in primary nasal pterygium surgery were evaluated.

Results: Postoperative patient discomfort was significantly lower with the sutureless techniques ($p < 0.001$), with fixation with cautery having the lowest rate of discomfort. Graft edema and ocular inflammation during the early postoperative period were significantly higher when fibrin glue techniques were used ($p < 0.001$). The recurrence rate did not show a statistically significant difference ($p = 0.682$) among the 4 groups.

Conclusion: In primary nasal pterygium surgery, limbal-conjunctival autograft fixation using cautery is the technique with the lowest postoperative discomfort rate and without a statistically significant increase in recurrence rate when compared to conventional suture and fibrin glue techniques.

Keywords: Fibrin glue, Limbal-conjunctival autograft, Pterygium

Introduction

A pterygium is a bulbar conjunctiva degeneration of multifactorial origin that can cause eye irritation, visual field abnormalities, astigmatism, and cosmetic alterations (1, 2). Susruta first described pterygium surgical removal in 1897 (3), and since then multiple surgical techniques have been reported, such as simple resection or bare sclera technique (4, 5), removal with primary closure or sliding conjunctiva flap (6, 7), and removal with concomitant beta irradiation (4, 8), but some of these techniques have recurrence rates as high as 50% (8-11).

Barraquer (12) first described the use of limbal-conjunctival autografts for the management of ocular surface burns; later this technique was used in pterygium surgery, at first using free conjunctiva autografts (13) and then limbal-conjunctival autografts, achieving recurrence rates below 2% (14-16).

The use of antimetabolites has also been proposed as a method to reduce recurrence rate (17-19); however, several

complications have been associated with these agents, such as globe perforation (20), scleral thinning and melting (21-24), iritis (20), cataracts (20), and corneal endothelial injury (25), and they have not demonstrated superiority over the limbal-conjunctival autograft technique without antimetabolites (14-16, 26-28).

Despite pterygium surgical technique advances, this surgery remains one of the anterior segment procedures that causes increased postoperative discomfort. Therefore, for several years, we have been seeking to reduce this discomfort in our patients by replacing conventional sutures with other graft fixation methods, such as commercial fibrin glue, autologous fibrin glue, and cautery.

Methods

A retrospective and descriptive study was performed; the eyes of patients who underwent surgery for primary nasal pterygium by 2 surgeons (L.F.M. and J.P.S.) over a period of 6 years were included. The limbal-conjunctival autograft technique was used and fixation was done using conventional sutures, commercial fibrin glue, autologous fibrin glue, or cautery.

Patients were excluded if a complete medical history was not available. The data recorded included postoperative patient discomfort according to analogue scale (Fig. 1) graft edema degree (0: absent, 1-2: mild, 3-4: moderate, 5: severe) and ocular inflammation degree (0: absent, 1-2: mild, 3-4: moderate, 5: severe) on days 1, 5, 8, 15, and 30. Complications such as graft dislocation, dehiscence, and cumulative

Accepted: December 6, 2016

Published online: January 18, 2017

Corresponding author:

Luis F. Mejía, MD
Cra 25 A #1-31, Of 914
Medellin, Colombia
lfmejia@une.net.co





Fig. 1 - Discomfort analog scale.

recurrence rate at 24 months for each technique were also recorded.

Surgical technique

The procedure was done under topical anesthesia; the pterygium removal technique and autograft procurement were the same for all the patients, as follows: the pterygium head was dissected from its central corneal edge toward the limbal one and then the body of the pterygium and its accompanying Tenon capsule were resected. The limbal and corneal surfaces were smoothed using a flat 3-mm-diameter diamond mill attached to a high-speed motor (AeroRotor) (29) followed by selective vessels cauterization. The free limbal-conjunctival graft was obtained from the superior limbus of the same eye.

The limbal-conjunctival autograft fixation was done with one of the following techniques:

1. Conventional suture: The graft's limbal edge was anchored to the limbus with 2 interrupted conjunctival (graft)-episcleral-conjunctival 10-0 nylon sutures, and the free borders with 5 interrupted conjunctival (graft)-conjunctival 10-0 nylon sutures.
2. Commercial fibrin glue: Around 0.2 mL of commercial glue with a thrombin concentration of 500 UI (Tissucol®; Baxter, Immuno AG, Austria) was applied to the surgical bed; then the autograft was positioned ensuring a limbus-to-limbus coincidence. After 90 seconds, the speculum was removed and graft stability while blinking was verified.
3. Autologous fibrin glue: 2 hours before the procedure, 6 mL of patient blood was obtained in a tube with citrate anticoagulant and centrifuged to separate plasma from red blood cells. A solution of 25 IU of thrombin and 85 mg of calcium gluconate per milliliter was prepared. Then, the surgical bed was dried, hemostasis was done, and a drop of patient plasma and a drop of thrombin/calcium gluconate solution were applied. Immediately after, the autograft was positioned ensuring a limbus-to-limbus coincidence. After 90 seconds, the speculum was removed and graft's stability while blinking was verified.
4. Electrocautery: Cautery with bipolar (YZ-II; Shanmu, Dalian, China) was performed in the graft's corners until a subtle whitening of the conjunctiva occurred; then the procedure was repeated at equidistant intervals on the rest of the graft's edges, for a total of 7 or 8 cautery points. Subsequently, the speculum was removed and graft stability while blinking was verified.

Upon finishing surgery, regardless of the technique used, polymyxin-neomycin-dexamethasone ointment was applied and the eye was occluded for 24 hours. On the following

day, fluorometholone 0.1% 5 times a day for 2 weeks and carboxymethylcellulose 1% 5 times a day for 3 months was started.

Statistical analysis

Statistical analysis was performed using Epidat and SPSS version 21. A $p < 0.05$ was considered statistically significant.

Results

A total of 169 eyes with a diagnosis of primary nasal pterygium were analyzed. Of these, autograft fixation was done with conventional suture in 90 patients (53.3%), with commercial fibrin glue in 29 patients (17.2%), with autologous fibrin glue in 21 patients (12.4%), and with cautery in 29 patients (17.2%).

Mean age was 40.5 years (range 18-62) and 51.5% were male. There were no statistically significant differences among the demographic characteristics of the 4 groups.

Discomfort

The suture group presented the greatest discomfort rate in the postoperative period, followed by both commercial and autologous fibrin glue groups, and finally by the cautery group, which was the group with the least discomfort. These differences between suture and sutureless groups were statistically significant from the first postoperative day for the cautery group ($p < 0.001$) and from the fifth day for the fibrin glue groups ($p < 0.001$). When comparing the fibrin glue groups with the cautery group, there was also a statistically significant difference ($p < 0.001$) in favor of the cautery. These differences kept their statistical significance until the 15th postoperative day (Fig. 2A).

Graft edema

The fibrin glue groups presented greater graft edema degree compared to suture and cautery fixation. This difference was statistically significant ($p < 0.001$) since the first postoperative day, with an edema peak at the 5th day and a progressive decrease of this difference. These differences kept their statistical significance until the 15th postoperative day (Fig. 2B).

Inflammation

Ocular inflammation, as graft edema, was greater for the fibrin glue groups compared with the other 2 groups since the first postoperative day ($p < 0.001$) and this difference persisted until the 15th day. The highest inflammation degree was on the 5th and 8th days for all the groups (Fig. 2C).

Complications

Graft dislocation occurred in 1 case of the cautery group (3.4%). During the early postoperative period, a statistically significant higher nasal border dehiscence rate in the commercial (37.9%) and autologous fibrin glue group (23.8%) were observed compared to the suture group (0%) and the cautery group (6.8%).

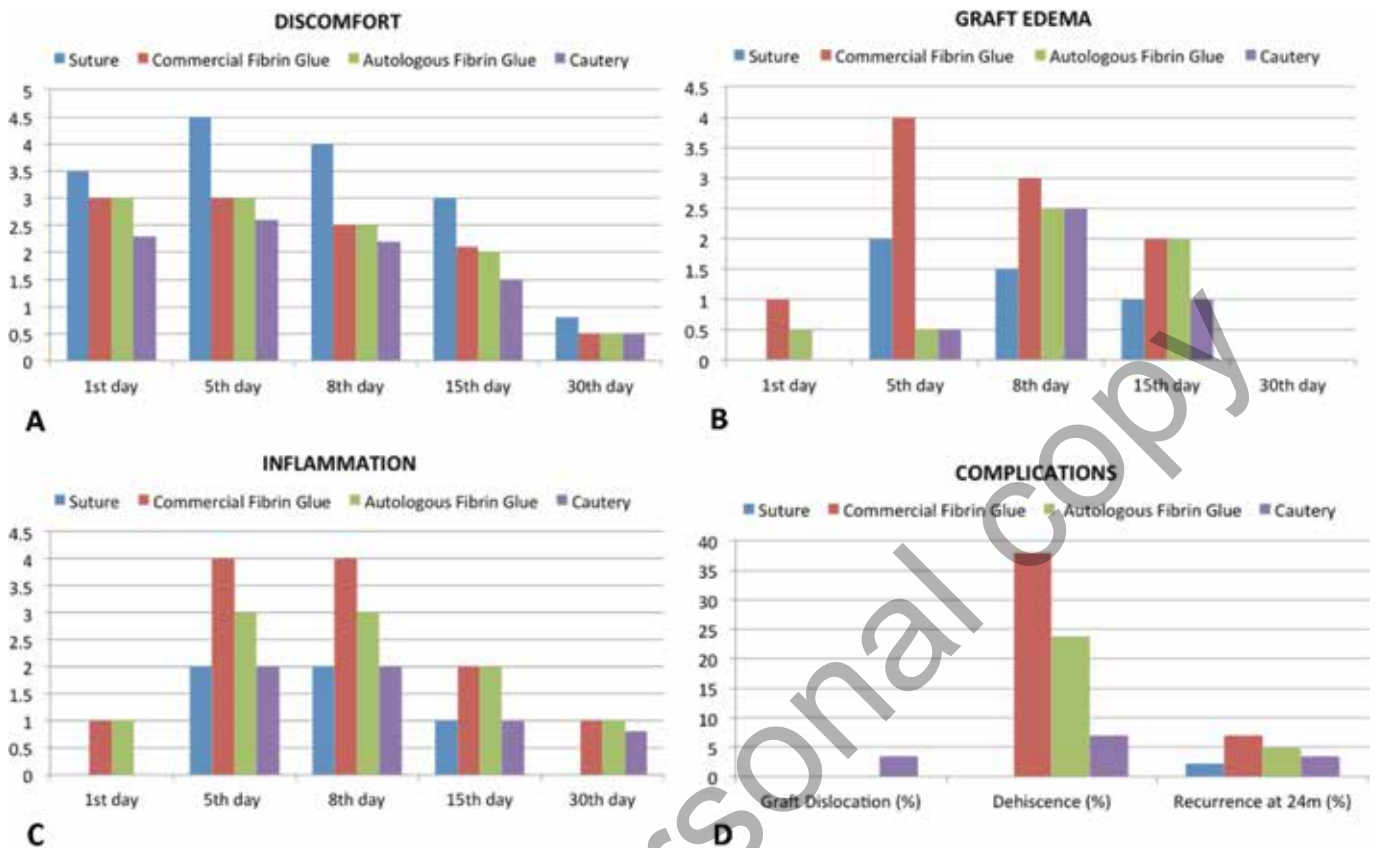


Fig. 2 - Comparison of the techniques for (A) discomfort, (B) graft edema, (C) ocular inflammation, and (D) complications.

The suture group had the lowest recurrence rate at 24 months (2.2% of cases). In the other 3 groups, the recurrence rate was 6.9% for the commercial fibrin glue group, 4.8% for autologous fibrin glue group, and 3.4% for the cautery group. There was no statistically significant difference among the 4 groups ($p = 0.682$) (Fig. 2D).

Discussion

Over the years, pterygium surgery has achieved important advances, which have mainly resulted in lower rates of recurrence, reaching values below 2% (16-18).

Currently, there are 2 important issues to resolve in pterygium surgery: the complex and recurrent case management and the patient's discomfort during the postoperative period, which makes this surgery one of the more uncomfortable anterior segment surgeries. Although such discomfort is explained by many factors, the sutures explain this discomfort after the first postoperative day.

Comparing 4 limbal-conjunctival autograft fixation methods in eyes in which all the other surgery steps were the same allowed us to demonstrate that there is a significant discomfort decrease in those patients in whom sutureless methods were used. This difference between suture and sutureless groups was statistically significant from the first postoperative day for the cautery group ($p < 0.001$) and from the fifth day for the fibrin glue groups ($p < 0.001$).

Both the graft edema and ocular inflammation rates were higher in the fibrin glue groups and achieved a statistically significant difference compared with conventional suture and cautery groups ($p < 0.001$). We consider that the higher graft edema level is due to the uniform edges sealing achieved with fibrin glues that avoid drainage of the fluid that accumulates underneath the graft. The effect on ocular surface of the chemical components included in fibrin glues could explain the higher inflammation level for these 2 groups.

Dehiscence rates were higher in the fibrin glue groups, especially of the nasal edge and in the first halves of the 2 series of patients with fibrin glue techniques. This is probably due to the fact that initially we were not taking large enough autografts and we did not take enough Tenon out of the graft and this led to retraction. In the second half of patients with each of these techniques, we used larger grafts with less Tenon, and zero dehiscence rates were achieved.

Recurrence is one of the most important considerations to favor one technique over another, and is therefore a fundamental issue to evaluate for each of the limbal-conjunctival autograft techniques compared in this study. The suture fixation technique had a lower recurrence rate, but did not achieve a statistically significant difference compared with sutureless techniques ($p = 0.682$).

In conclusion, the technique of choice for primary nasal pterygium surgery is the complete removal of the pterygium and reconstruction using a limbal-conjunctival autograft,

which can be fixed with sutures, commercial fibrin glue, autologous fibrin glue, or cautery, providing similar cosmetic and functional results, but generating less postoperative discomfort when using sutureless techniques.

Disclosures

Financial support: No financial support was received for this submission.

Conflict of interest: None of the authors has conflict of interest with this submission.

References

1. Yanoff M, Duker J. Pterygium and Conjunctival Degenerations. *Ophthalmology*, 4th ed: St. Louis: Mosby Elsevier, 2014; 203-205.
2. Krachmer JH, Mannis MJ. Corneal and Conjunctival Degenerations. *Cornea*, 3rd ed. Philadelphia: Mosby Elsevier, 2011; 901-917.
3. Rosenthal JW. Chronology of pterygium therapy. *Am J Ophthalmol*. 1953;36(11):1601-1616.
4. King JH Jr. The pterygium; brief review and evaluation of certain methods of treatment. *AMA Arch Ophthalmol*. 1950;44(6): 854-869.
5. Portney GL. Bare sclera, scleral cautery and corticosteroid therapy of endemic pterygium in the Navajo Indian. *Am J Ophthalmol*. 1969;67(5):759-761.
6. Lei G. Surgery for pterygium using a conjunctival pedunculated flap slide. *Br J Ophthalmol*. 1996;80(1):33-34.
7. McCoombes JA, Hirst LW, Isbell GP. Sliding conjunctival flap for the treatment of primary pterygium. *Ophthalmology*. 1994;101:169-173.
8. MacKenzie FD, Hirst LW, Kynaston B. Recurrence rate complications after beta irradiation for pterygia. *Ophthalmology*. 1991;98:1776-1780.
9. Tan DTH, Chee SP, Dear KBG. Effect of pterygium morphology on pterygium recurrence in a controlled trial comparing conjunctival autografting with bare sclera excision. *Arch Ophthalmol*. 1997;115:1235-1240.
10. Lewallen S. A randomized trial of conjunctival autografting for pterygium in the topics. *Ophthalmology* 1989;96:1612-1614.
11. Youngson RM. Recurrence of pterygium after excision. *Br J Ophthalmol*. 1972;56:120-125.
12. Barraquer JI. The corneo-conjunctival limbus reconstruction before corneal grafting in: King JH McTigue, eds. *Proceedings of the First Cornea World Congress*, pp 351-354. Washington DC: Butterworths; 1965.
13. Serrano F. Plastia conjuntival libre en la cirugía del pterigion. *Arch Soc Am Oftal Optom*. 1977;12:97-102.
14. Mejía LF, Sanchez JG, Escobar H. Management of primary pterygia using free conjunctival and limbal-conjunctival autografts without antimetabolites. *Cornea*. 2005;24:972-975.
15. Masters JS, Harris DJ Jr. Low Recurrence Rate of Pterygium After Excision With Conjunctival Limbal Autograft: A Retrospective Study With Long-Term Follow-Up. *Cornea*. 2015;34: 1569-1572.
16. Young AL, Leung GY, Wong AK, Cheng LL, Lam DS. A randomised trial comparing 0.02% mitomycin C and limbal conjunctival autograft after excision of primary pterygium. *Br J Ophthalmol*. 2004;88:995-997.
17. Martins TG, Costa AL, Alves MR, Chammas R, Schor P. Mitomycin C in pterygium treatment. *Int J Ophthalmol*. 2016;9: 465-468.
18. Altay Y, Balta O. Intraoperative application of 5-fluorouracil and mitomycin C as chemoadjuvants in primary pterygium surgery. *Turk J Med Sci*. 2016;46:321-327.
19. Tsim NC, Young AL, Jhanji V, Ho M, Cheng LL. Combined conjunctival rotational autograft with 0.02% mitomycin C in primary pterygium surgery: a long-term follow-up study. *Br J Ophthalmol*. 2015;99:1396-1400.
20. Rubinfeld RS, Pfister RR, Stein RM, Foster CS, Martin NF, Stoleru S, et al. Serious complications of topical mitomycin-C after pterygium surgery. *Ophthalmology*. 1992;99:1647-1654.
21. Dunn JP, Seamone CD, Ostler HB, Nickel BL, Beallo A. Development of scleral ulceration and calcification after pterygium excision and mitomycin therapy. *Am J Ophthalmol*. 1991;112: 343-344.
22. Tsai YY, Lin JM, Shy JD. Acute scleral thinning after pterygium excision with intraoperative mitomycin C: a case report of scleral dellen after bare sclera technique and review of the literature. *Cornea*. 2002;21:227-229.
23. Safianik B, Ben-Zion I, Garzosi HJ. Serious corneoscleral complications after pterygium excision with mitomycin C. *Br J Ophthalmol*. 2002;86:357-358.
24. Lindquist TP, Lee WB. Mitomycin C-associated scleral stromalysis after pterygium surgery. *Cornea* 2015;34:398-401.
25. Avisar R, Avisar I, Bahar I, Weinberger D. Effect of mitomycin C in pterygium surgery on cornea endothelium. *Cornea*. 2008;27:559-561.
26. Ari S, Caca I, Yildiz ZO, Sakalar YB, Dogan E. Comparison of mitomycin C and limbal-conjunctival autograft in the prevention of pterygial recurrence in Turkish patients: A one-year, randomized, assessor-masked, controlled trial. *Curr Ther Res Clin Exp*. 2009;70:274-281.
27. Jiang J, Gong J, Li W, Hong C. Comparison of intra-operative 0.02% mitomycin C and sutureless limbal conjunctival autograft fixation in pterygium surgery: five-year follow-up. *Acta Ophthalmol*. 2015;93:568-572.
28. Zheng K, Cai J, Jhanji V, Chen H. Comparison of pterygium recurrence rates after limbal conjunctival autograft transplantation and other techniques: meta-analysis. *Cornea*. 2012;31: 1422-1427.
29. Reinoso S. Cirugía del pterigion mediante Aerorotor. *Arch Soc Am Oftal Optom*. 1977;12:109-130.